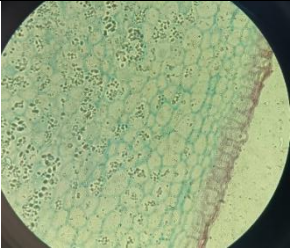
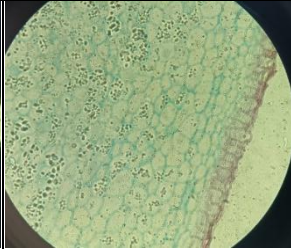
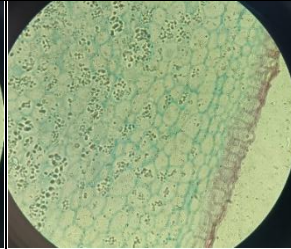
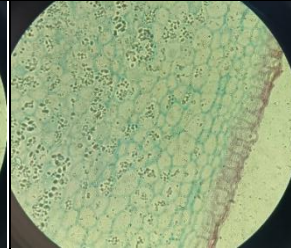
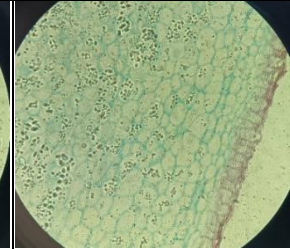
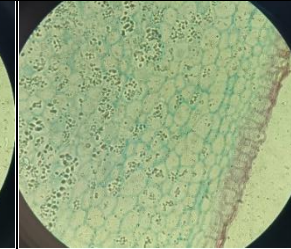
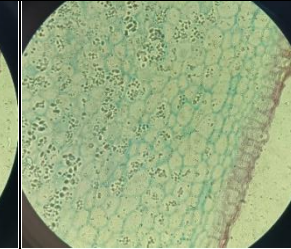
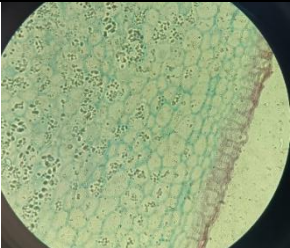
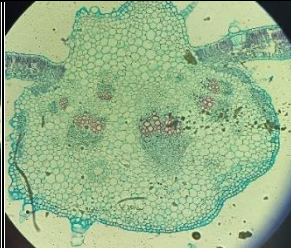
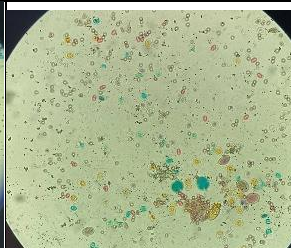
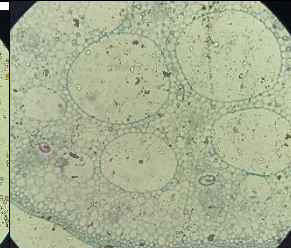


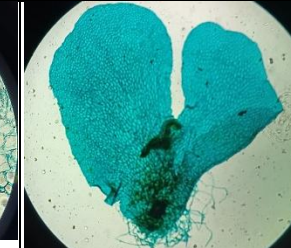
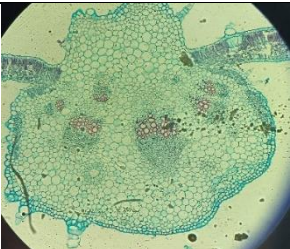
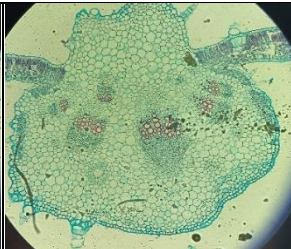
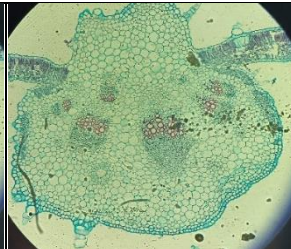
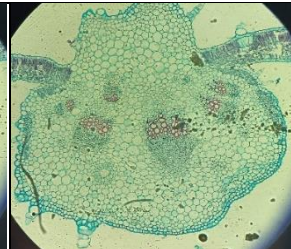
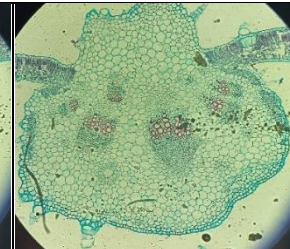
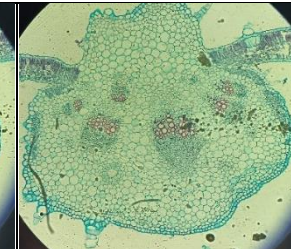
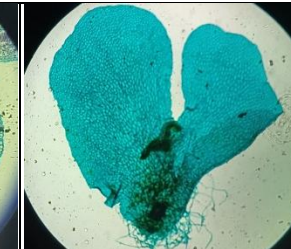
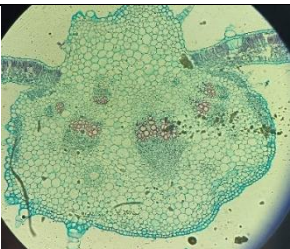
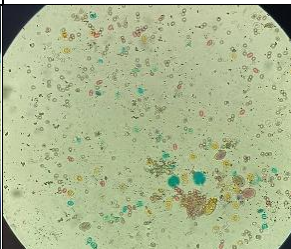
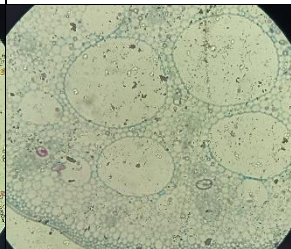

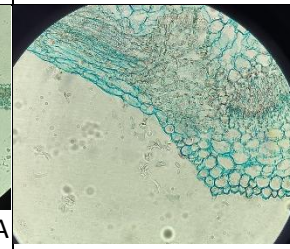
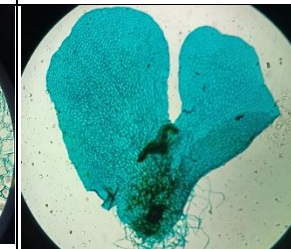
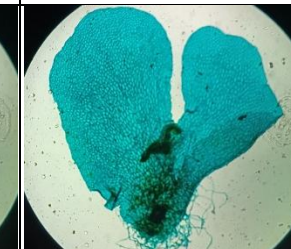
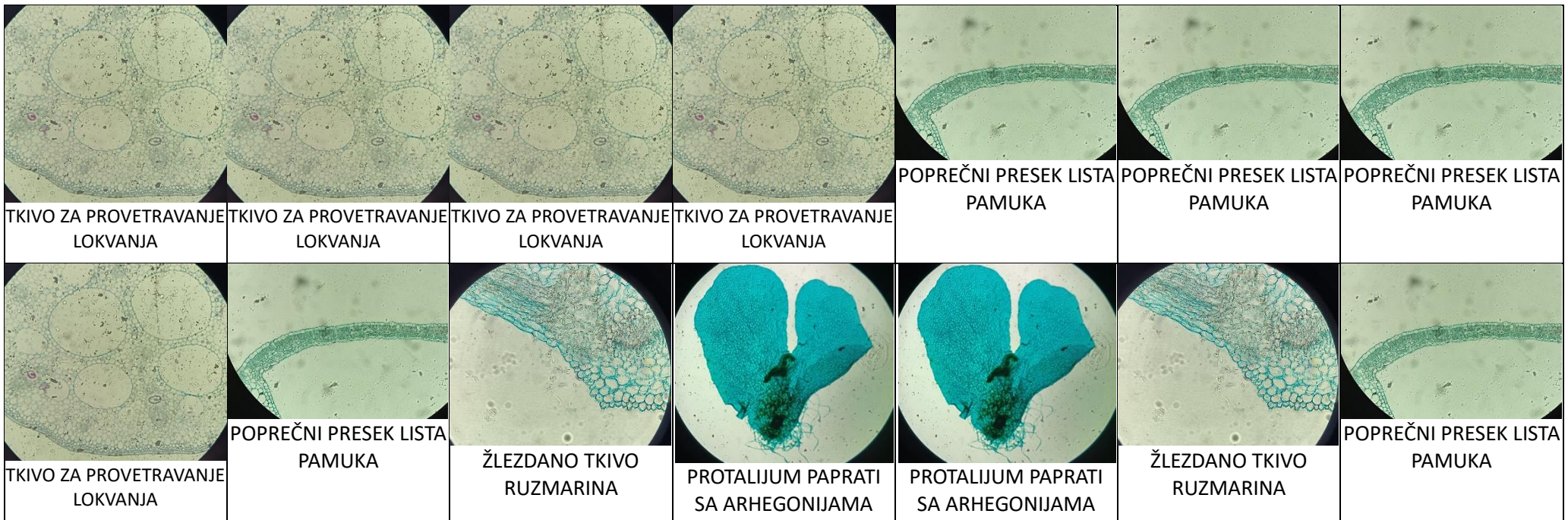
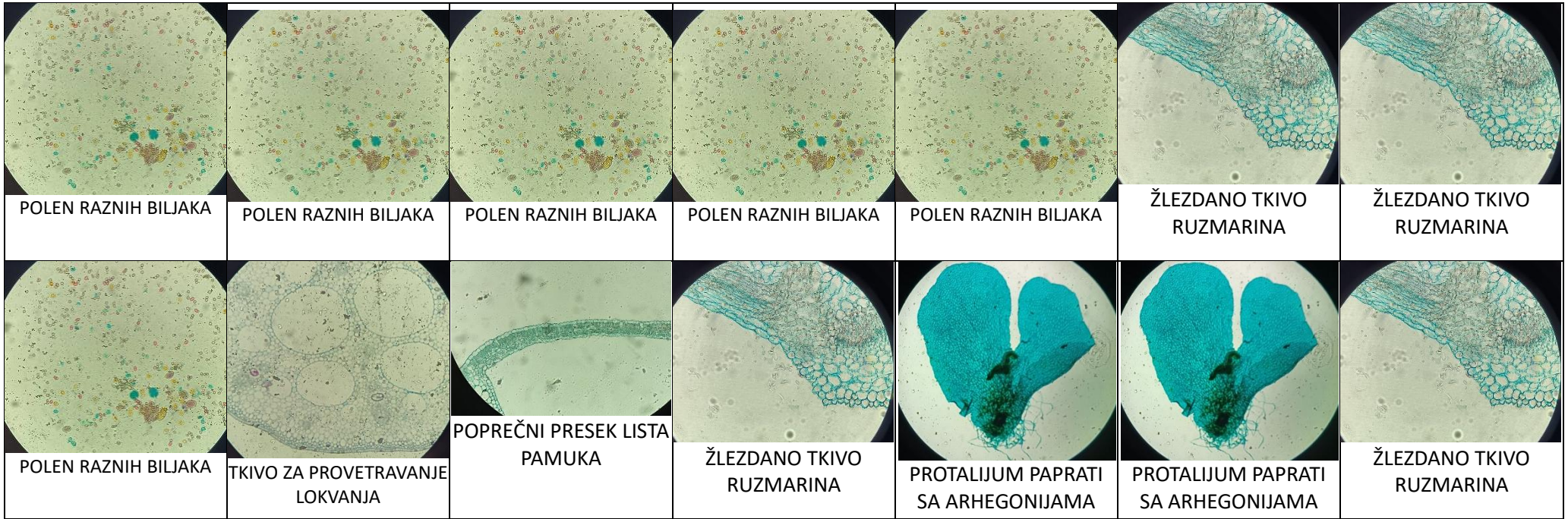


BILJNA TKIVA

1. NIVO



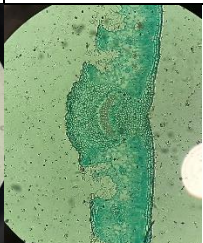
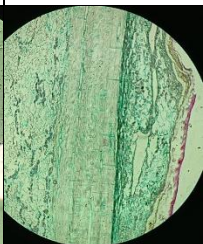



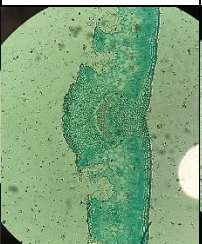
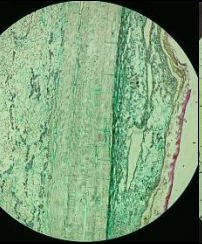


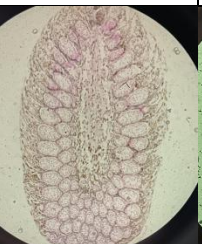
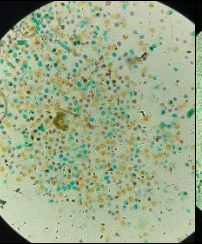
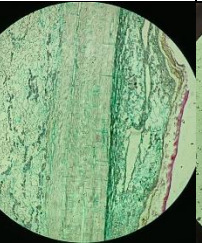



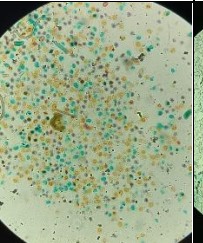
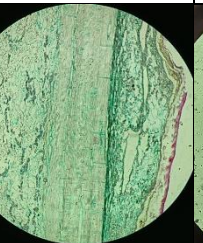
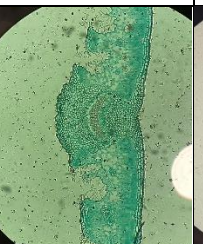
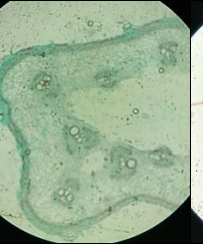

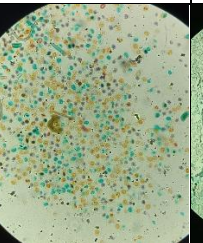
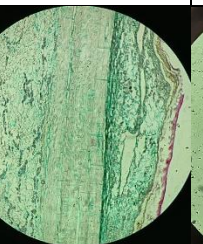
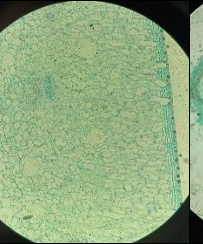
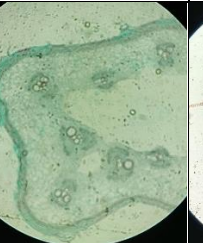

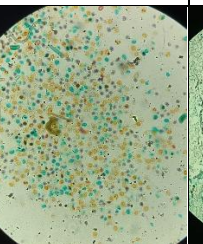
						
TKIVO ZA MAGACIONIRANJE KROPMIRA	TKIVO ZA MAGACIONIRANJE KROPMIRA	TKIVO ZA MAGACIONIRANJE KROPMIRA	TKIVO ZA MAGACIONIRANJE KROPMIRA	TKIVO ZA MAGACIONIRANJE KROPMIRA	TKIVO ZA MAGACIONIRANJE KROPMIRA	TKIVO ZA MAGACIONIRANJE KROPMIRA
						
TKIVO ZA MAGACIONIRANJE KROPMIRA	SPROVODNO TKIVO LISTA SUNCOKRETA	POLEN RAZNIH BILJAKA	TKIVO ZA PROVETRAVANJE LOKVANJA	POPREČNI PRESEK LISTA PAMUKA	ŽLEZDANO TKIVO RUZMARINA	PROTALIJUM PAPTATI SA ARHEGONIJAMA

						
SPROVODNO TKIVO LISTA SUNCOKRETA	SPROVODNO TKIVO LISTA SUNCOKRETA	SPROVODNO TKIVO LISTA SUNCOKRETA	SPROVODNO TKIVO LISTA SUNCOKRETA	SPROVODNO TKIVO LISTA SUNCOKRETA	SPROVODNO TKIVO LISTA SUNCOKRETA	PROTALIJUM PAPTATI SA ARHEGONIJAMA
						
SPROVODNO TKIVO LISTA SUNCOKRETA	POLEN RAZNIH BILJAKA	TKIVO ZA PROVETRAVANJE LOKVANJA	POPREČNI PRESEK LISTA PAMUKA	ŽLEZDANO TKIVO RUZMARINA	PROTALIJUM PAPTATI SA ARHEGONIJAMA	PROTALIJUM PAPTATI SA ARHEGONIJAMA



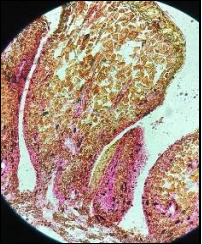
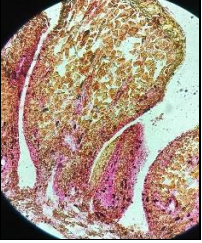

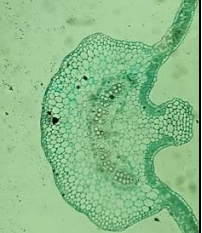
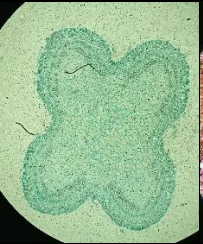
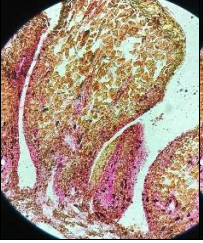
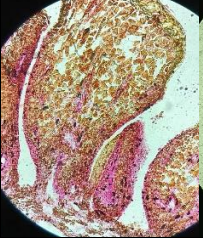

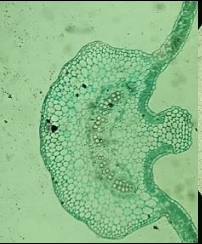
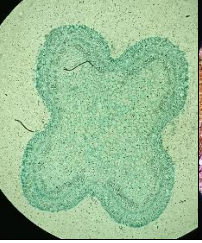
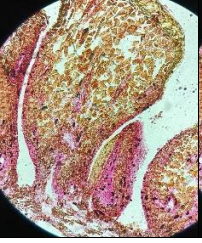
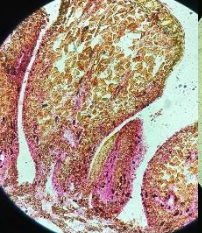
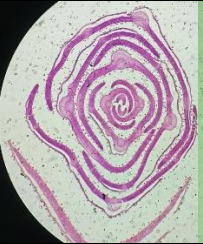
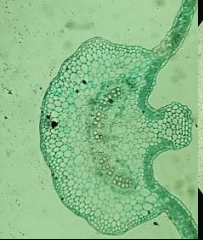

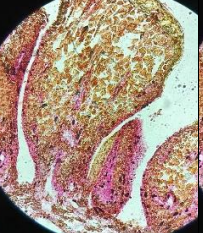
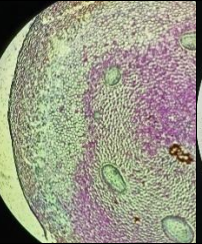
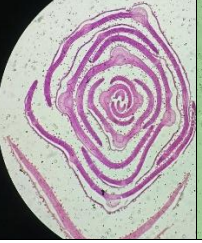
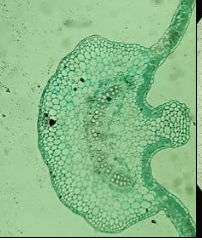
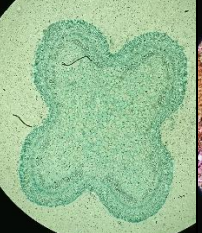
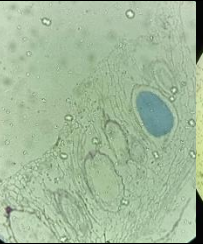
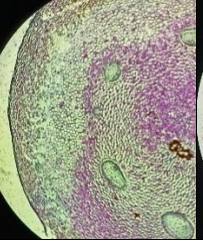
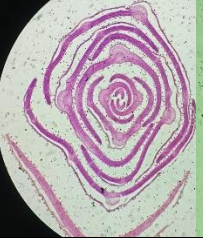
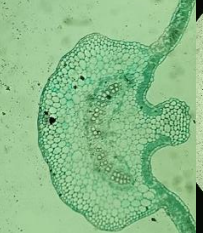
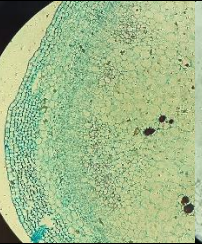
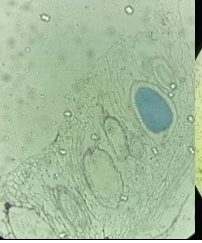
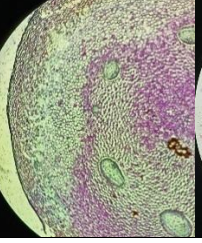
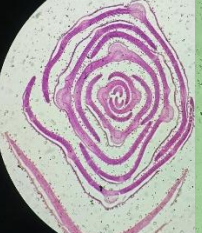
BILJNA TKIVA

2. NIVO

<p>ČELIJE KAKTUSA SA KRISTALIMA</p>		<p>PRESEK KROZ MLADU ŠIŠARKU BORA</p>		<p>LIST OLIANDERA (NERIUM)</p>		<p>POPREČNI PRESEK KROZ STABLO BORA</p>	
<p>ČELIJE KAKTUSA SA KRISTALIMA</p>		<p>ZATVORENI PROVODNI SNOPIČI STABLA BUNDEVE</p>		<p>LIST OLIANDERA (NERIUM)</p>		<p>POPREČNI PRESEK KROZ STABLO BORA</p>	
<p>ČELIJE KAKTUSA SA KRISTALIMA</p>		<p>ZATVORENI PROVODNI SNOPIČI STABLA BUNDEVE</p>		<p>ANTERIDIJA MAHOVINE</p>		<p>POPREČNI PRESEK KROZ STABLO BORA</p>	
<p>ČELIJE KAKTUSA SA KRISTALIMA</p>		<p>ZATVORENI PROVODNI SNOPIČI STABLA BUNDEVE</p>		<p>ANTERIDIJA MAHOVINE</p>		<p>POLEN BORA</p>	
<p>ČELIJE KAKTUSA SA KRISTALIMA</p>		<p>ZATVORENI PROVODNI SNOPIČI STABLA BUNDEVE</p>		<p>ANTERIDIJA MAHOVINE</p>		<p>POLEN BORA</p>	
<p>ČELIJE KAKTUSA SA KRISTALIMA</p>		<p>ZATVORENI PROVODNI SNOPIČI STABLA BUNDEVE</p>		<p>ANTERIDIJA MAHOVINE</p>		<p>POLEN BORA</p>	
<p>ČELIJE KAKTUSA SA KRISTALIMA</p>		<p>ZATVORENI PROVODNI SNOPIČI STABLA BUNDEVE</p>		<p>ANTERIDIJA MAHOVINE</p>		<p>POLEN BORA</p>	

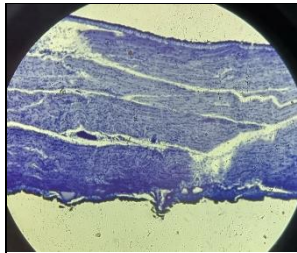
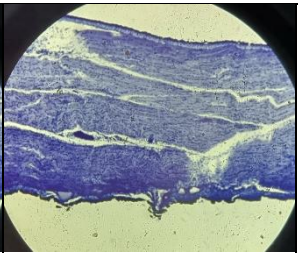
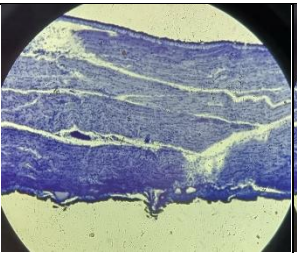
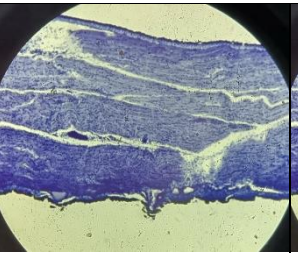
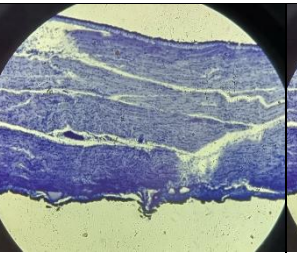
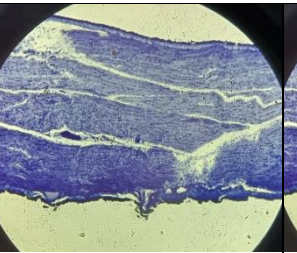
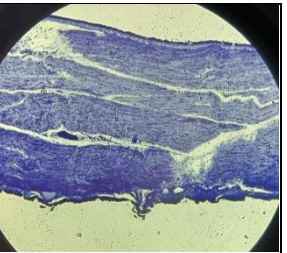
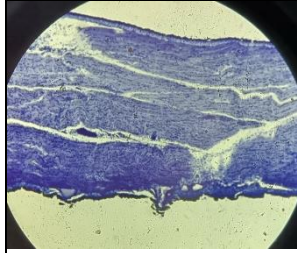


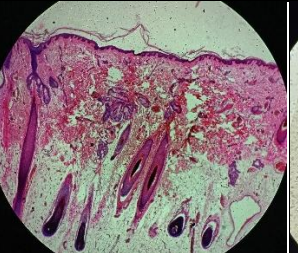
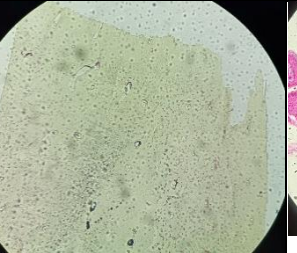

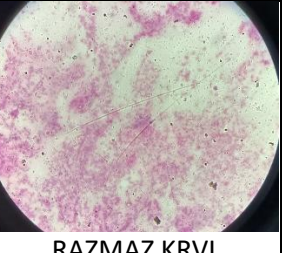
BILJNA TKIVA







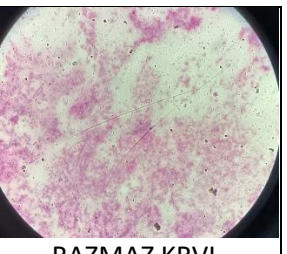


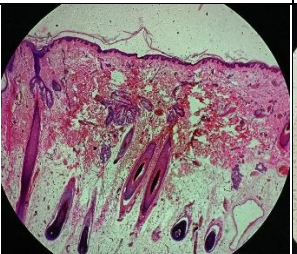
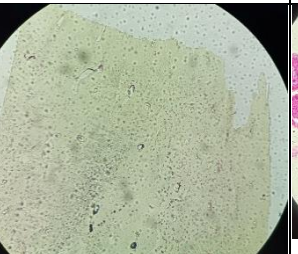

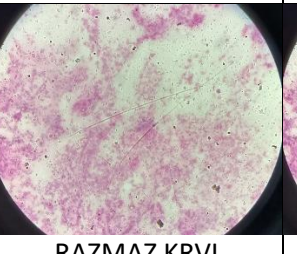
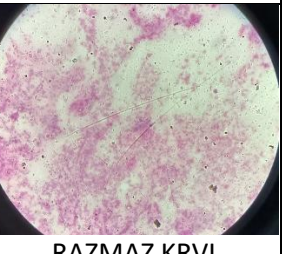
3. NIVO




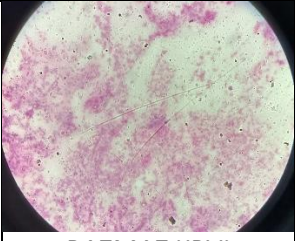
STABLO ZOVE SA PARENHIMATIČNIM ČELIJAMA		ZAŠTITNI I OPLODNI LISTIĆI ŠIŠARKE BORA		KOLENHIM U STABLU MRTVE KOPRIVE		POPREČNI PRESEK LISTA PAMUKA	
STABLO ZOVE SA PARENHIMATIČNIM ČELIJAMA		PRESEK KROZ ANTERIDIJU MARŠANCIJE		KOLENHIM U STABLU MRTVE KOPRIVE		POPREČNI PRESEK LISTA PAMUKA	
STABLO ZOVE SA PARENHIMATIČNIM ČELIJAMA		PRESEK KROZ ANTERIDIJU MARŠANCIJE		RIZOMI PAPPATI		ČETINE SMREKE	
STABLO ZOVE SA PARENHIMATIČNIM ČELIJAMA		PRESEK KROZ ANTERIDIJU MARŠANCIJE		RIZOMI PAPPATI		ČETINE SMREKE	
STABLO ZOVE SA PARENHIMATIČNIM ČELIJAMA		PRESEK KROZ ANTERIDIJU MARŠANCIJE		RIZOMI PAPPATI		ČETINE SMREKE	
STABLO ZOVE SA PARENHIMATIČNIM ČELIJAMA		PRESEK KROZ ANTERIDIJU MARŠANCIJE		RIZOMI PAPPATI		ČETINE SMREKE	
STABLO ZOVE SA PARENHIMATIČNIM ČELIJAMA		PRESEK KROZ ANTERIDIJU MARŠANCIJE		RIZOMI PAPPATI		ČETINE SMREKE	

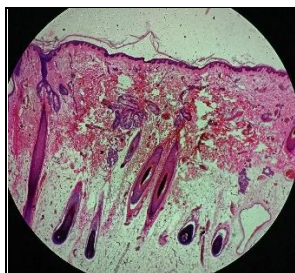

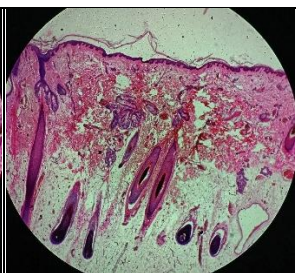
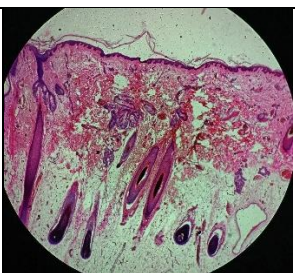
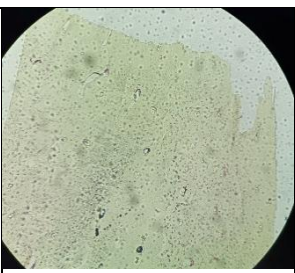
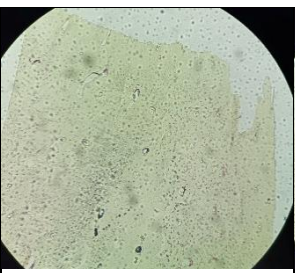
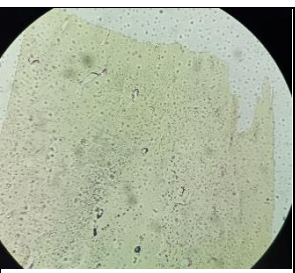
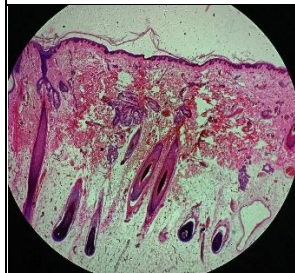
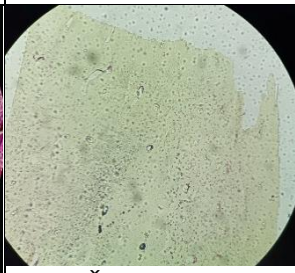

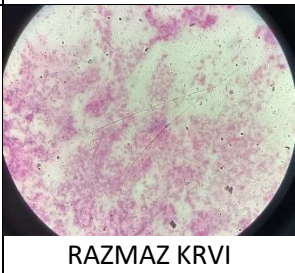
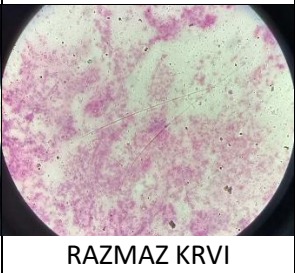
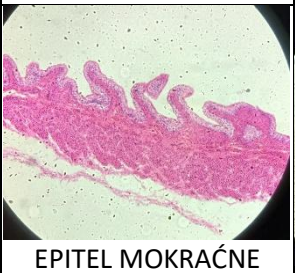
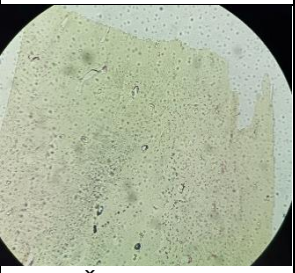
ŽIVOTINJSKA TKIVA

1.NIVO

						
POPREČNO- -PRUGASTI MIŠIĆ	POPREČNO- -PRUGASTI MIŠIĆ	POPREČNO- -PRUGASTI MIŠIĆ	POPREČNO- -PRUGASTI MIŠIĆ	POPREČNO- -PRUGASTI MIŠIĆ	POPREČNO- -PRUGASTI MIŠIĆ	POPREČNO- -PRUGASTI MIŠIĆ
						
POPREČNO- -PRUGASTI MIŠIĆ	ZID TANKOG CREVA	NERVNO TKIVO MALOG MOZGA	KOŽA	KOŠTANO TKIVO	EPITEL MOKRAĆNE BEŠIKE	RAZMAZ KRVI (ERITROCITI)

						
ZID TANKOG CREVA	ZID TANKOG CREVA	ZID TANKOG CREVA	ZID TANKOG CREVA	ZID TANKOG CREVA	ZID TANKOG CREVA	RAZMAZ KRVI (ERITROCITI)
						
ZID TANKOG CREVA	NERVNO TKIVO MALOG MOZGA	KOŽA	KOŠTANO TKIVO	EPITEL MOKRAĆNE BEŠIKE	RAZMAZ KRVI (ERITROCITI)	RAZMAZ KRVI (ERITROCITI)

						
NERVNO TKIVO MALOG MOZGA	NERVNO TKIVO MALOG MOZGA	NERVNO TKIVO MALOG MOZGA	NERVNO TKIVO MALOG MOZGA	NERVNO TKIVO MALOG MOZGA	EPITEL MOKRAĆNE BEŠIKE	EPITEL MOKRAĆNE BEŠIKE
						
NERVNO TKIVO MALOG MOZGA	KOŽA	KOŠTANO TKIVO	EPITEL MOKRAĆNE BEŠIKE	RAZMAZ KRVI (ERITROCITI)	RAZMAZ KRVI (ERITROCITI)	EPITEL MOKRAĆNE BEŠIKE

						
KOŽA	KOŽA	KOŽA	KOŽA	KOŠTANO TKIVO	KOŠTANO TKIVO	KOŠTANO TKIVO
						
KOŽA	KOŠTANO TKIVO	EPITEL MOKRAĆNE BEŠIKE	RAZMAZ KRVI (ERITROCITI)	RAZMAZ KRVI (ERITROCITI)	EPITEL MOKRAĆNE BEŠIKE	KOŠTANO TKIVO

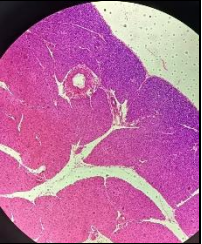
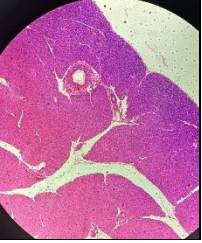
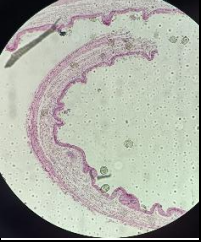
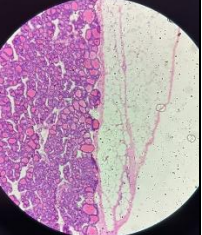
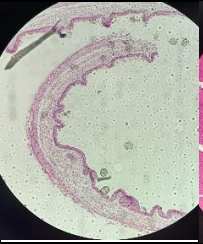
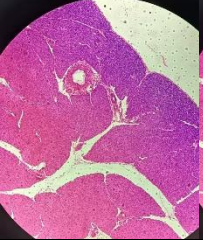
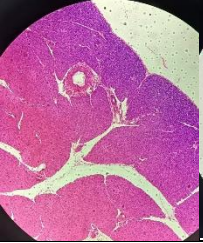
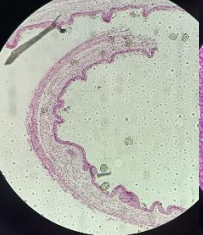
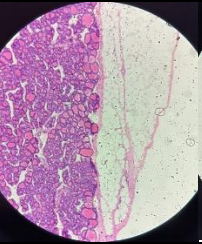
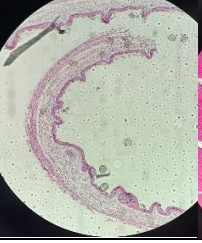
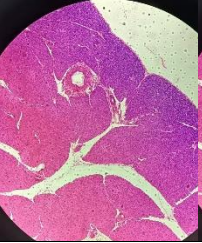
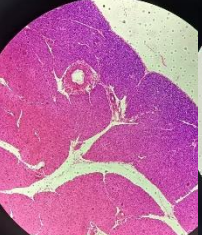
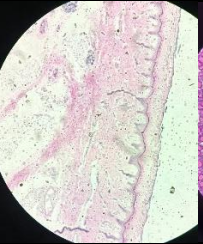
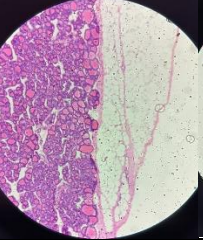
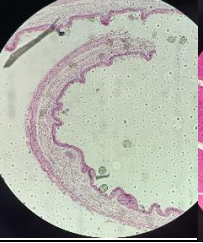
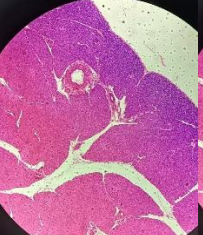

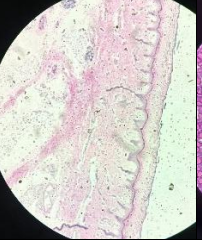
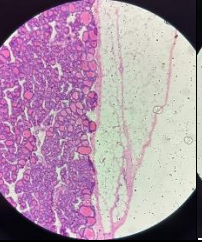
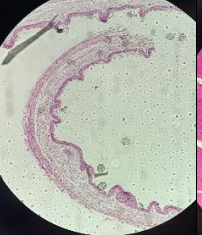
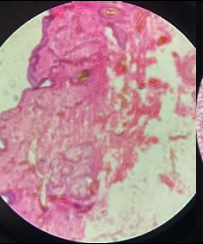
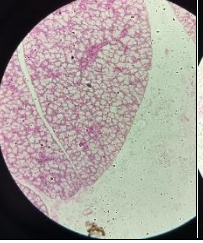
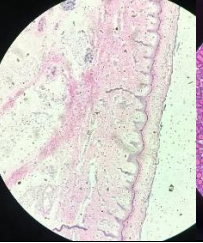
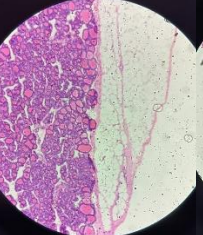
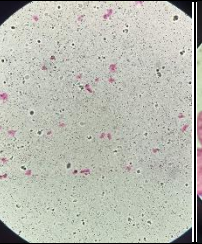
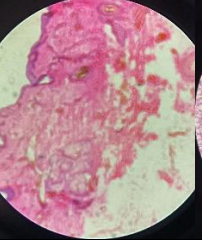
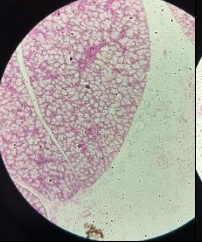
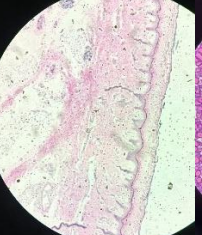
ŽIVOTINJSKA TKIVA



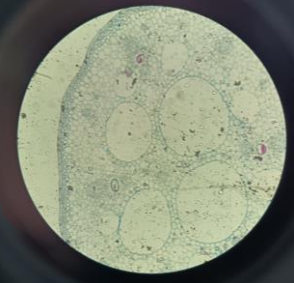
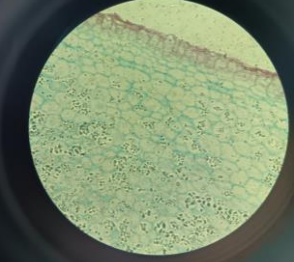
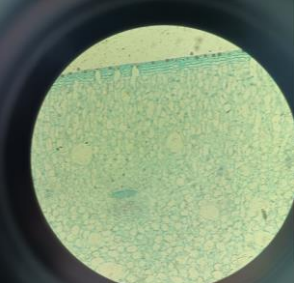
2. NIVO

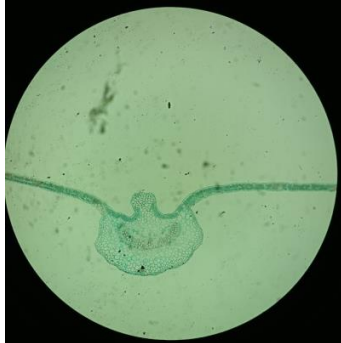KRAJNIK SA LIMFNIMI ČVOROVIMA		POPREČNO-PRUGASTI MIŠIĆ ČOVEKA		URETER ČOVEKA		ZID AORTE	
KRAJNIK SA LIMFNIMI ČVOROVIMA		VELIKI MOZAK ČOVEKA		URETER ČOVEKA		ZID AORTE	
KRAJNIK SA LIMFNIMI ČVOROVIMA		VELIKI MOZAK ČOVEKA		PLUĆA ČOVEKA		PRESEK KROZ TESTIS ČOVEKA	
KRAJNIK SA LIMFNIMI ČVOROVIMA		VELIKI MOZAK ČOVEKA		PLUĆA ČOVEKA		PRESEK KROZ TESTIS ČOVEKA	
KRAJNIK SA LIMFNIMI ČVOROVIMA		VELIKI MOZAK ČOVEKA		PLUĆA ČOVEKA		PRESEK KROZ TESTIS ČOVEKA	
KRAJNIK SA LIMFNIMI ČVOROVIMA		VELIKI MOZAK ČOVEKA		PLUĆA ČOVEKA		PRESEK KROZ TESTIS ČOVEKA	
KRAJNIK SA LIMFNIMI ČVOROVIMA		VELIKI MOZAK ČOVEKA		PLUĆA ČOVEKA		PRESEK KROZ TESTIS ČOVEKA	

ŽIVOTINJSKA TKIVA

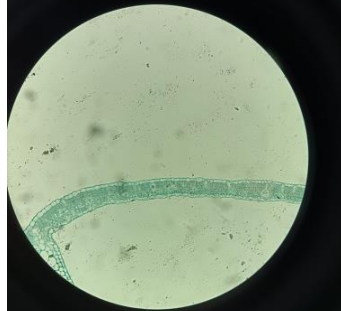
3.NIVO

EPITELNE ČELIJE USNE DUPLJE ČOVEKA		LAGERHANSOVA OSTRICA PANKREASA		ŽUČNA KESA		TIROIDNA ŽLEZDA	
EPITELNE ČELIJE USNE DUPLJE ČOVEKA		MUSKULATURA SRCA ČOVEKA		ŽUČNA KESA		TIROIDNA ŽLEZDA	
EPITELNE ČELIJE USNE DUPLJE ČOVEKA		MUSKULATURA SRCA ČOVEKA		PODJEZIČNA ŽLEZDA		TIROIDNA ŽLEZDA	
EPITELNE ČELIJE USNE DUPLJE ČOVEKA		MUSKULATURA SRCA ČOVEKA		PODJEZIČNA ŽLEZDA		KOŽA SA ZNOJNIM ŽLEZDAMA	
EPITELNE ČELIJE USNE DUPLJE ČOVEKA		MUSKULATURA SRCA ČOVEKA		PODJEZIČNA ŽLEZDA		KOŽA SA ZNOJNIM ŽLEZDAMA	
EPITELNE ČELIJE USNE DUPLJE ČOVEKA		MUSKULATURA SRCA ČOVEKA		PODJEZIČNA ŽLEZDA		KOŽA SA ZNOJNIM ŽLEZDAMA	
EPITELNE ČELIJE USNE DUPLJE ČOVEKA		MUSKULATURA SRCA ČOVEKA		PODJEZIČNA ŽLEZDA		KOŽA SA ZNOJNIM ŽLEZDAMA	

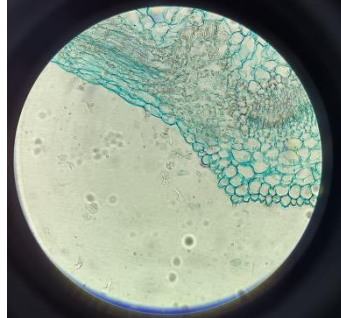
Preparat biljnih tkiva	POJAM
	<p>Vegetaciona kuoja korena</p>
	<p>Vegetaciona kupa stabla</p>
	<p>Stabljika lokvanja sa aerenhimom bogata zvezdastim dlakama</p>
	<p>Ćelije krompira sa zrcima skroba</p>
	<p>Ćelije kaktusa sa kristalima</p>



Poprečni presek kroz lisni nerv lista pamuka



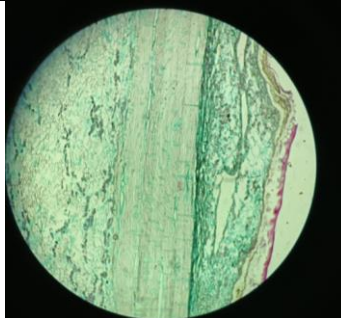
Poprečni presek kroz list pamuka






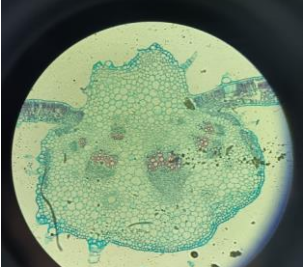
Žlezdane dlake ruzmarina

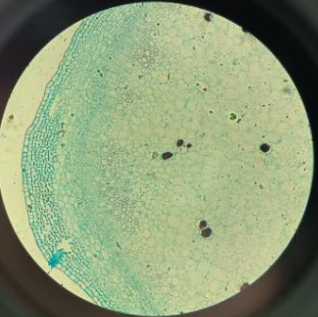
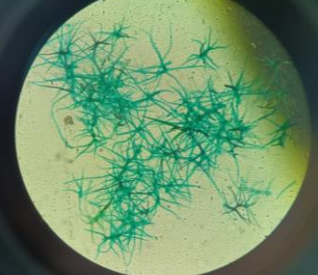
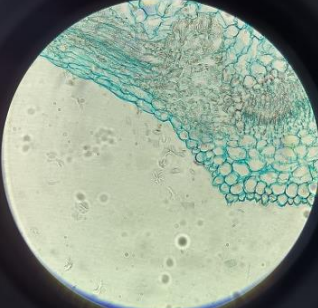
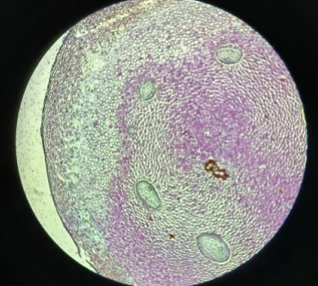
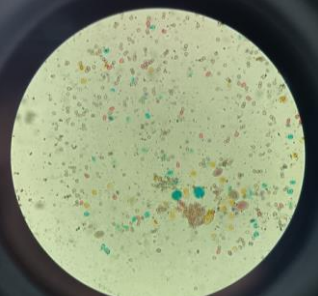


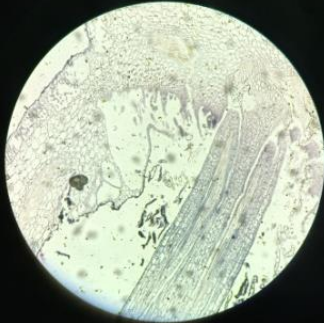
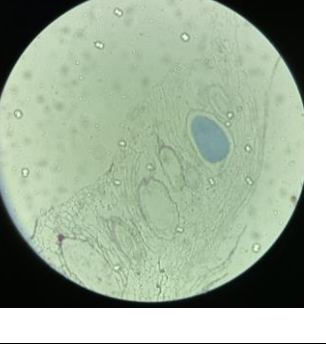

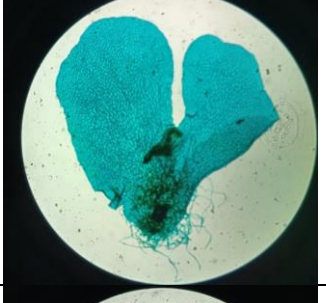

Stablo bora


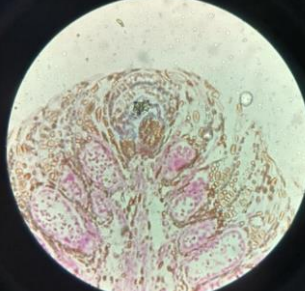
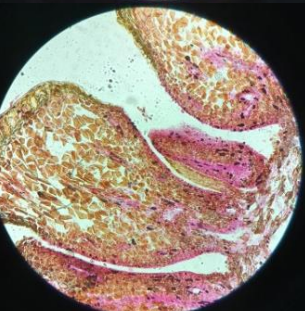
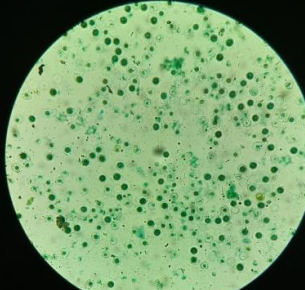
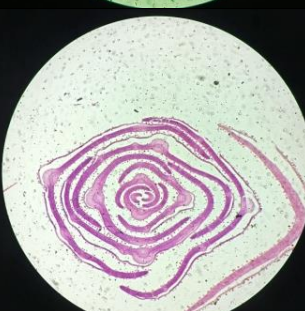


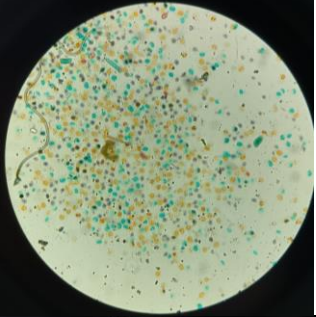
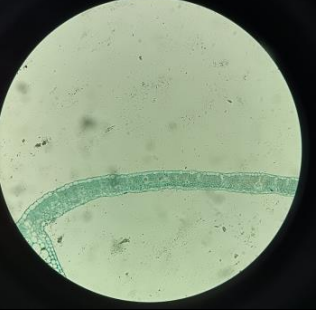

Poprečan presek kroz stablo bora, mrtva kora

	<p>Kolenhim u stablu mrtve koprive</p>
	<p>Stablo bundeve sa provodnim snopićima</p>
	<p>Izolovani sprovodni elementi</p>
	<p>Presek kroz lisni nerv oleandera</p>
	<p>List suncokreta sa dlakama</p>

	<p>Stablo zove sa parenhimatičnim ćelijama i plutom</p>
	<p>Razgranate dlake lista kraljevske trešnje</p>
	<p>Žlezdana dlaka ruzmarina</p>
	<p>Rizom paprati</p>
	<p>Polen raznih biljaka</p>

	<p>Maršancija presek kroz arhegoniju</p>
	<p>Maršancija prese kroz anteridiju</p>
	<p>Anteridije mahovine</p>
	<p>Protalijum paprati sa arhegonijama</p>
	<p>Protalijum paprati sa anteridijama</p>

	<p>Presek kroz mladu šišarku bora</p>
	<p>Presek kroz mladu šišarku sa mejozom</p>
	<p>Zaštitni I oplodni listoći mlade šišarke bora</p>
	<p>Spore evizetuma</p>
	<p>Vrh smrče (presek kroz četine)</p>

	<p>Polen bora</p>
	<p>Poprečni presek kroz list pamuka</p>
	<p>Poprečni presek kroz list pamuka (hlorenhimi epidermis)</p>

Životinjka tkiva preparati	Pojam
	<p>Koža sa znojnim žlezdama</p>
	<p>Koža čoveka</p>
	<p>Epitelne ćelije usne duplje</p>
	<p>Nokat</p>
	<p>Uzdužni presek poprečno-prugasto mišićno tkivo čoveka</p>

	<p>Muskulatura srca čoveka</p>
	<p>Podjezična pljuvačna žleza čoveka</p>
	<p>Krajnik sa limfnim čvorovima</p>
	<p>Zid aorte</p>
	<p>Krvni razmaz-eritrociti čoveka</p>

	<p>Zid creva</p>
	<p>Zid tankog creva</p>
	<p>Slepo crevo</p>
	<p>Žučna kesa</p>
	<p>Pluća čoveka</p>

	<p>Ureter čoveka</p>
	<p>Mokraćna bešika</p>
	<p>Poprečni presek kroz testis čoveka</p>
	<p>Spermatozoidi čoveka</p>
	<p>Štitna (tiroidna)žlezda</p>

	<p>Gušterača (pancreas čoveka)</p>
	<p>hrskavica</p>
	<p>Kost</p>
	<p>Mali mozak čoveka</p>
	<p>Veliki mozak čoveka</p>